USGS
science for a changing world

Zinc poisoning of waterfowl in the Tri-State Mining District

W. Nelson Beyer, Patuxent Wildlife Research Center, U.S. Geological Survey

Introduction

The Tri-State Mining District was once the world's greatest producer of lead-zinc ores. The names of the local towns, such a Galena and Zincville, recall the District's early mining history, dating back to the middle of the 19th century. Although it is long since residents no longer shouldered pick and shovel, the remnants of mining dominate the landscape. Metals were dispersed into the habitat during mining, milling and smelting. Metals were dispersed further in sediments carried by streams and on trucks spreading waste rock on roads. The U. S. Fish and Wildlife Service had little evidence of poisoning of wild birds in the District, other a textbook on waterfowl by Phillips and Lincoln (1930) that reported deaths of many mallards, pintails, and teal on Spring River, near Riverton, KS, in 1923. In response to a request from the U. S. Fish and Wildlife Service, we investigated whether metals in the District were harming wild birds. In this poster, we discuss only zinc in waterfowl.

The District covers about three thousand square kilometers, where Oklahoma and Kansas abut Missouri. There are several sources of metals in the District. Milled mine waste, locally known as "chat", contains Pb, Zn, Cd and other elements that were not separated from the ore. Much of this chat has been processed more than once and it had been dumped in massive piles throughout the District. Some of these piles remain, especially in Oklahoma, but many have been dispersed as the chat was sold for various uses. They are interspersed with wildlife habitat, ranches and houses. Ores were at first smelted locally, at the mining sites, on log piles or furnaces (Magoo 1996), but eventually smelting was centralized in Joplin, MO (1881), in Galena, KS (1893), and in Hockerville, OK (1918). Flotation tailings are fine-grained materials derived from the froth flotation milling process that are deposited in settling ponds. The remnants of these ponds may be especially contaminated.

A chat pile in Oklahoma. Chat is ground waste rock left over after most of the metals have been removed during milling. The word chat is a local term coming from chert, the dominant rock where the ores are found. Chat may still have high concentrations of lead, cadmium, zinc and other metals. Much of the chat in the Tri-State Mining District has been dispersed throughout the area during road construction, but some large piles remain in Oklahoma.

How zinc poisons birds

Although zinc is recognized as having poisoned many kinds of organisms (fish, aquatic invertebrates, trees, mosses, lichens, salamanders, soil invertebrates and microbes), zinc poisoning has never been reported in wild birds. The veterinary literature, however, includes several well-documented cases of zinc poisoning in captive birds that have swallowed zinc-coated hardware. Because of these cases we understand the pathology of zinc poisoning and, when combined with tissue analyses, we can diagnose zinc poisoning reliably. We understand the kinetics of zinc in birds from controlled dosing studies. Zinc is closely regulated in body tissues, and as the dose increases moderately, tissues concentrations remain relatively constant. Animals collected from moderately contaminated sites may show tissue concentrations similar to those in reference sites. There comes a point, though, at which regulation fails. Zinc is excreted mainly in the bile, through the pancreas, but the excreted zinc in the gut may be reabsorbed in a enterohepatic loop. It is not surprising then, that the pancreas is a target organ of zinc. In addition to being directly toxic to tissue, zinc may be toxic by inducing deficiencies of other elements, especially copper.

Results

Seventeen waterfowl (8 mallards, 3 Canada geese, 2 common mergansers, 2 ring-necked ducks, a green-winged teal and a lesser scaup) were collected, examined at necropsy, and analyzed for zinc tissue concentrations. Five mallards from the Neosho Wildlife Area in Kansas were collected and treated in the same way to serve as references. Concentrations of zinc in livers and kidneys were significantly elevated in the sample population, as shown below.

Table 1. Mean concentrations of Pb, Cd and Zn in tissues of birds from the Tri-State Mining District (Tri) and reference (ref.) sites.

Species and tissue [N]	Pb mean	Pb SD	Cd mean	Cd SD	Zn mean	Zn SD
	mg/kg, dry wt					
Waterfowl						
liver (Tri) [17]	4.1*	(9.6)	2.1	(3.1)	440**	(710)
liver (ref.) [5]	0.57	(0.36)	0.92	(0.59)	93	(30)
kidney (Tri) [17]	11**	(14)	17	(30)	210*	(240)
kidney (ref.) [5]	0.86	(0.42)	7.4	(4.6)	80	(8.3)
blood (Tri) [11]	2.1**	(1.5)	<0.04	-	41	(40)
blood (ref.) [5]	0.35	(0.23)	<0.04	-	22	(2.5)
pancreas (Tri) [17]	2.9**	(3.8)	0.81	(1.0)	530	(700)
pancreas (ref) [5]	0.18	(0.078)	0.49	(0.30)	210	(59)

The examinations of three Canada geese collected were particularly telling. A gander (Goose 1) was observed unable to fly or escape in the field. The examining veterinarian found its wings drooped and its legs were paralyzed, a sign of zinc poisoning reported in previous studies (Gasaway and Buss 1972; Zdziarski et al. 1994; Grandy et al. 1968). Hepatic concentrations in all three geese were well above normal values and were comparable to those reported in mallards killed by zinc under experimental conditions, as shown below.

Table 2. Concentrations of Zn detected in tissues of Canada geese from the Tri-State Mining District compared to those in control and poisoned mallards.

Waterfowl	Liver	Kidney	Pancreas
	mg/kg of Zn, dry weight		
Tri-State Mining District			
Goose 1	2900	970	260
Goose 2	1000	510	2400
Goose 3	1100	560	2300
Mallard laboratory references (means)[a]	180	90	300
Zn-poisoned mallards (means)[a]	1100-1600	1000-1700	4200-8900

[a]Gasaway and Buss (1972)

In addition, all three of the geese had histopathological pancreatic lesions associated with severe zinc poisoning (Zdziarski et al., 1994). The pancreas has an endocrine function associated with producing insulin and an exocrine function associated with bile production, in what are called "acinar" cells (meaning that they resemble clusters of grapes). Zinc attacks the acinar cells. In the mildest cases observed, the cells were atrophied and lacked zymogen, and in the most extreme, shown below, the tissue was hyperplastic and the acini were separated by fibrous tissue, which forms in response to the damage.

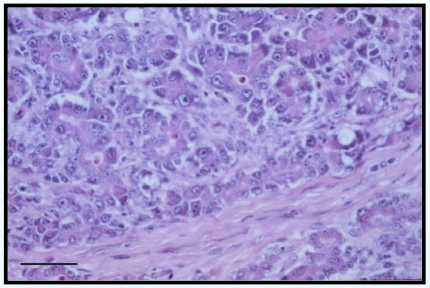

This pancreas from a Canada goose (No. 2) had a concentration of 2400 mg/kg dry weight of Zn. Note disorganized, misshapen cells, marked variation in nuclei size, cytoplasmic vacuoles, and interacinar fibrosis. Scale bar = 40 mm.

More recently, a trumpeter swan was sighted on a millpond in Oklahoma and was watched for a few weeks until it became weakened. The swan was then transported to the College of Veterinary Medicine, Kansas State University, where it was treated with chelation therapy. It died within a day, however. A histopathological examination showed the same pancreatic lesions reported in the zinc-poisoned geese and the tissue analyses showed that the zinc was elevated to toxic concentrations. Dr. James Carpenter diagnosed the swan as zinc poisoned.

This three-year old female trumpeter swan was released from Iowa in an effort to bolster wild populations. Trumpeter swans are the largest and rarest swans in the world and are not normally found in Oklahoma. She settled on a millpond, shown here, located east of Picher, Oklahoma, and gradually weakened and lost mobility. Dr. James Carpenter of the University of Kansas College of Veterinary Science tried unsuccessfully to rehabilitate her with chelation treatment. After an examination at necropsy and analysis of tissues for metals, the swan was diagnosed as zinc poisoned.

Conclusions

1) Waterfowl habitat within the Tri-State Mining District is so severely contaminated with mining wastes that waterfowl are being poisoned with zinc.

2) We have documented the first reported instance of zinc poisoning in wild birds.

3) The route of exposure has not yet been documented, but both Canada geese and trumpeter swans are known to feed on plant material such as tubers that are associated with sediments.

Acknowledgements

The overall study in the Tri-State Mining District is being conducted by John Dalgarn of the Bureau of Indian Affairs (Miami Agency, P. O. Box 391, Miami, Oklahoma), Rafael Mateo of the Faculty of Veterinary, Universitat Autonoma de Barcelona, Bellaterra, Spain, Lou Sileo of the National Wildlife Health Center (U.S. Geological Survey, Madison, WI), W. Nelson Beyer, John B. French, and James Spann of the Patuxent Wildlife Research Center, (U.S. Geological Survey, Laurel, MD), Suzanne Dudding of the U.S. Fish and Wildlife Service (222 South Houston, Suite A, Tulsa OK) and John Miesner of the U.S. Fish and Wildlife Service (Manhattan, Kansas).

References

Gasaway, W. C. and I. O. Buss. (1972). Zinc toxicity in the mallard duck. Journal of Wildlife Management, 36, 1107-1117.

Grandy, J.W.,IV, L. N. Locke, and G. E. Bagley. (1968). Relative toxicity of lead and five proposed substitute shot types to pen-reared mallards. Journal of Wildlife Management, 32, 483-488.

Magoo S (1996) Site Evaluation Findings Report, Tar Creek NPL Site, Oklahoma City Field Area. Contract Number 1422-N651-C4-3049. July 24, 1996. 52 pp. and attachments.

Phillips, J. C. and F. C. Lincoln. (1930). American Waterfowl: Their Present Situation and the Outlook for their Future. Boston: Houghton Mifflin Co.

Zdziarski, J.M., M. Mattix, R.M. Bush, R.J. Montali. (1994). Zinc toxicosis in diving ducks. Journal of Zoo and Wildlife Medicine, 25, 438-445.